

# Health Observations Before and After Amalgam Removal \*

**Dr.med.dent. Paul Engel**  
 Lyss-Strasse 24, 2560 Nidau  
 Switzerland

## Introduction

From 1972-1993 (5 years internship and 16 years of my own practice) amalgam was by far the most prevalent dental filling material used by me (in the side tooth area). Different reasons led me to abandon use of this material in the spring of 1994. An amalgam-critical work which had appeared in the FASEB journal in 1989 (Hahn et al.) was certainly an important reason for my decision. Moreover, some of my own earlier observations (e.g. with Pat. No 2 and Pat. No 73) and the fact that alternatives to amalgam were widely available, were equally important reasons for me to discontinue using amalgam, a material I had considered highly reliable before.

From the 1800 patients whom I had treated in the last four years, roughly 90 wished to have their partially intact amalgam fillings -often done by me - replaced by another material (mostly composites and compomere). Predominantly, these were patients with certain health problems, who had been influenced by an acquaintance or via different media and had learned of the possible toxic effect of mercury from amalgam.

On the one hand, I wanted to find out which symptoms existed before amalgam removal had taken place. On the other hand, I wanted to record health modifications which patients had described after the removal.

## Results

In the table 1, symptoms indicated by the patients were listed. Qualitative health improvements were described in each case with the terms "much better", "better", "somewhat better", "no improvement", "worsening". In the diagram wider below gender and age distribution of patients are differentiated.

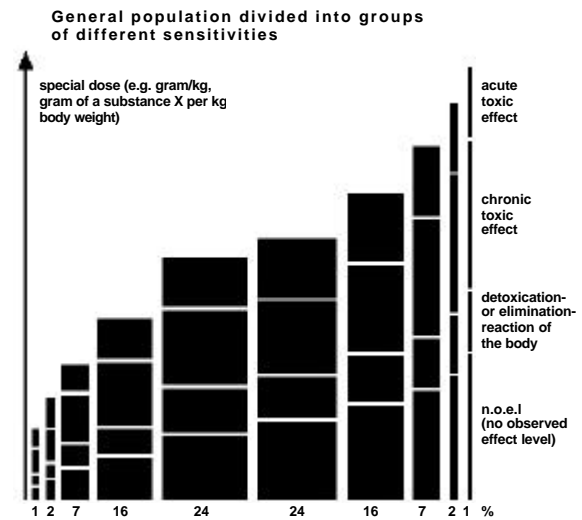
## Discussion

52 women and 23 men (i.e. approx. 4% of the patients treated by me in the last 4 years), mostly over 30 years old, complained of chronic symptoms such as migraine (36x), headache (32x), gastro-intestinal disturbances (27x), neck tension (25x), paraesthesia (19x), dizziness

(18x), allergies (13x), vision disturbances (13x), back pain (12x), mental disorder (12x), joint pain (10x) and shoulder/arm pain (10x). After removing the amalgam, 68% of the patients believed their health had become "much better", 12% "better", 9% "somewhat better", 7% had experienced "no improvement" whatsoever, and 1% "worsening".

Certainly this is an amazing, almost unbelievable result. Had the patients or had the dentist embellished the results? I do not believe this.

Do the patients described belong to a particularly "amalgam-sensitive" group? On the following graph, based on the "Kieler Amalgam Gutachten 1997" the distribution of the differently sensitive groups of a population is represented:



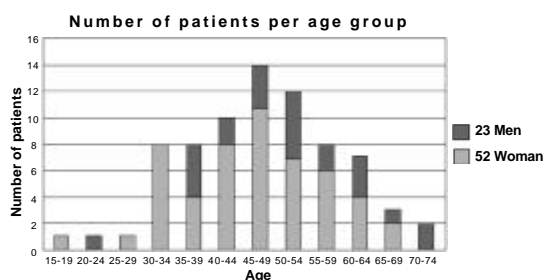
Whereas a large majority of the population feel little or no disease characteristics during a certain toxic agent impact, those 10% at the lefthand side of the graph already display acute-toxic symptoms.

I do not know whether the large part of the 75 patients described can belong only to such a particularly mercury-sensitive group. Connected with this is also the question of the importance of the estimated number of unknown cases. For example, patient No 41 had been treated by me for many years without ever once mentioning that he had constantly suffered from severe migraine. How many undiscovered patients with similar health problems as described above could be among the other patients of mine?

On the following diagram: the age specification is related to the year 1997. No conclusions can be made concerning the actual beginning of the symptoms. Why did more than as twice as many

## Health Observations Before and After Amalgam Removal

women than men have their amalgam fillings removed? Are they more sensitive at a certain age than men to amalgam questions or are they simply more often ill than men?



### Conclusion

Certainly it will be necessary to pursue further investigations and to observe health modifications with the patients who have already been examined. Will their health continue to improve? Henceforth, in any case, I will pay more attention in future to the health modifications after amalgam removal than before. Patients would have to be asked more systematically about the time frame of the origin of their disease and its development as well as the point in time when amalgam removal was undertaken. Above all, however - and that is probably the main purpose of this work - I would like to know whether other colleagues have made any similar observations.

### General methodical observations

In order to protect the patient - and the dentist - from mercury vapor, the "Clean Up" suction system (Scania Dental AB Sweden) was used. This allows mercury vapor in a patient's mouth to be reduced by a factor 100. The rubber dam was sealed with "Oraseal" (Ultradent Products). As filling material composites (direct fillings and inlays) and also compomere were applied. In general, two fillings per session were replaced. Despite preventive measures, some particularly sensitive patients reacted strongly to the amalgam removal (e.g. Pat. No 30, 29,72) with a temporary aggravation of their symptoms. In such cases, a longer break of about a month between the individual sessions had to be allowed for.

### Empirical data of 75 patients

Usually the patients appeared after one year for "recall". Their state of health was always inquired about. The last statements were attached into the table. It was interesting that sometimes together with other positive feedback disappearing symptoms were referred which had not ever been mentioned before. This concerned above often "neck tension", which was noticeable

to me only after many recalls. And also the improvement of symptoms such as "mental problems", "fatigue", "concentration difficulties, and "memory problems" were often only mentioned explicitly afterwards by patients.

It was remarkable how often symptoms such as "headache" and (above all) "migraine" had substantially improved or even completely disappeared even before all the amalgam fillings had been removed.

Even the complete disappearance of a very strong Neurodermatitis (Pat. No 63), i.e. a symptom, which nobody else had ever mentioned was indeed impressive.

Just as amazing was the disappearance of shoulder / arm pain (e.g. Pat. No 20, 69, 67, 50, 27), persisting for many years, which had completely disappeared. Something similar can be reported also with the "allergies" (e.g. Pat. No 37).

Whereas the symptoms of "migraine", "dizziness", "neck tension, "sight impairment" and "paraesthesia" improved seemingly fast or even totally disappeared after amalgam removal, this did not seem to be the case with patients suffering from "stomach / intestine" disorder symptoms.

Finally, a significant improvement could be observed in one case (Pat. No 17) with "MS" diagnosis.

### Literature

L.J. Hahn, R. Kloiber, M.J. Vimy, Y. Takahashi, and F.L. Lorscheider: "Dental "silver" tooth fillings: a source of mercury exposure revealed by whole body image scan and tissue analysis". FASEB journal 2640 vol. 3 Dec. 1989.

Kieler Amalgam Gutachten 1997, available from GZM, Seckenheimerstr.111, 68239 Mannheim

\* English translation of "Beobachtungen über die Gesundheit vor und nach Amalgamentfernung", Schweiz. Monatschr. f. Zahnmed. (Vol 108: 8/1998) by S. Dodd.





### **Empirical data of 75 patients**

#### **Patient No. 1** R.M., male 1954

symptoms: dizziness, low blood pressure, joint pains  
13 amalgams, 1<sup>st</sup> filling removed 5.93, last 5.94  
11.96: practically no dizziness left, stable blood pressure  
2.98: all mentioned symptoms in order  
own health assessment: much better

#### **Patient No. 2** S.M., male 1955

symptoms: headaches, neck pains, balance impaired, night blindness, double vision (sometimes sees “double” road dividing lines), peripheral vision flickering  
12 amalgams, 1<sup>st</sup> filling removed 12.92, last 9.93  
6.96: no more dizziness, occasional headaches, no double vision  
neck pains 70% better  
11.97 continuing health improvement  
own health assessment: much better

#### **Patient No. 3** H.H., male 1951

symptoms: acute joint pain, “tennis elbow” related pain, forced to abandon career as a carpenter  
13 amalgams, 1<sup>st</sup> filling removed 9.85, last 4.86  
6.97: health improved with less pain  
own health assessment: better

#### **Patient No. 4** N.U., female 1963

symptoms: constant sickness, dizziness, hearing problems, sudden weight loss and gain, frequent nasal and sinus infections, gynecological problems, hair loss, joint pain, exhaustion, allergies, paraesthesia  
14 amalgams, 1<sup>st</sup> filling removed 6.95, last 5.96  
5.96 considerable health improvement  
7.97: health still improved, no hair loss, no joint pain, work reassumed  
4.98 health improvement, psychic stability, decrease in shyness, Tinnitus better, hearing better, no more joint or neck pain, no more exhaustion symptoms, 70% work capacity (previously near complete work incapacity), continued gastro-intestinal disturbances and low blood pressure  
own health assessment: much better

#### **Patient No. 5** B.R., female 1964

symptoms: MS, numbness in lower body, difficulties with equilibrium  
12 amalgams, 1<sup>st</sup> filling removed 6.95, last 8.95  
5.96: no improvement  
5.97: no improvement  
9.97: deterioration of symptoms  
own health assessment: worsening

#### **Patient No. 6** W.H., female 1951

symptoms: neck tension, sudden severe headaches from the neck to the head, head pains like “lightning flashes”, migraines, repeated feeling of sickness, extreme nausea, back pains, difficulties with equilibrium, day and night eye pain, ice cold hands and feet, weakness and stiffness in knees and legs, tingling in extremities, taste of metal, gastro-intestinal disturbances, sensitive to weather changes, rheumatismal pains, feeling down mentally, feelings of despair (no organic causes found medically therefore assigned as “psychosomatic” although the patient feels this is not the case, can no longer think properly, skull seems to “explode”, almost fully work impaired  
15 amalgams, 1<sup>st</sup> filling removed 10.94, last 10.95  
10.95: walks better, less weakness in legs  
8.96: equilibrium much better, headaches improved, psychically much more motivated, occasional tingling in hands, no more stomach sourness, no more nausea  
10.97: janitorial work resumed, back pain improved, no more uneasiness, has not been feeling better in years, steady health improvement  
7.98: further corporal and psychic improvement, less depressive than before, “has a new life”  
own health assessment: much better

## Health Observations Before and After Amalgam Removal

### **Patient No. 7** R.H., female 1952

symptoms: numerous headaches and migraine, sinus infections

15 amalgams, 1<sup>st</sup> filling removed 2.93, last 6.94

5.95: headaches much better

11.96: headaches with nausea connected to pylorus problems

2.98: in July 1997 hospitalized due to severe colon infection, continuing

gastro-intestinal disturbances, compared to before far fewer headaches (last 5 weeks before)

own health assessment: better

### **Patient No. 8** K.M., female 1946

14 amalgams, 1<sup>st</sup> filling removed 6.91 last 11.95

severe headaches after each amalgam removal

1.96: still numerous headaches

3.97: same

3.98: headaches somewhat better, but neck problems still remain

own health assessment: somewhat better

### **Patient No. 9** S.F., female 1957

symptoms: migraine

12 amalgams, 1<sup>st</sup> filling removed 1.92, last 7.96

10.96: practically no more migraine

7.97: same

own health assessment: much better

### **Patient No. 11** K.G., male 1934

symptoms: severe, recurrent migraine

11 amalgams, 1<sup>st</sup> filling removed 12.94, last 10.96

already after removal of half the fillings far fewer migraine

6.97: no more migraine

4.98: no more migraine for two years

own health assessment: much better

### **Patient No. 12** R.K., male 1943

symptoms: frequent headaches, gastro-intestinal disturbances

13 amalgams, 1<sup>st</sup> filling removed 12.93, last 11.96

12.93: piece of amalgam removed from former alveole

due to fewer headaches, patient wishes to have all fillings removed

11.96: headaches continue, but less severe and often

digestion problems continue, but no more acid stomach

2.98: feels much better, no more headaches

own health assessment: much better

### **Patient No. 13** V.L., female 1937

symptoms: migraine

9 amalgams, 1<sup>st</sup> filling removed 6.95, last 10.95

7.96: migraine less often and less severe

11.97: migraine almost gone

own health assessment: much better

### **Patient No. 14** M.J., female 1963

symptoms: stomach / intestinal problems

16 amalgams, 1<sup>st</sup> filling removed 6.95, last 11.96

11.97: intestines much better, stomach still bad

own health assessment: somewhat better

## Health Observations Before and After Amalgam Removal

### **Patient No. 15** F.M., female 1949

symptoms:

10 amalgams, 1<sup>st</sup> filling removed 1.95, last 11.95

12.96: fewer and pains

5.97: fewer pains, use of hands returns

1.98: all pain fully gone, plays the piano again

own health assessment: much better

### **Patient No. 16** M.M., female 1963

symptoms: migraine and headaches before menstruation, dizziness, gastro-intestinal disturbances

6 amalgams, 1<sup>st</sup> filling removed 12.94, last 1.97

9.95: migraine, headache and dizziness gone

10.97: same

own health assessment: much better

### **Patient No. 17** P.T., female 1948

symptoms: MS, 7 years before neuritis on optical nerve (first colors perceived wrong then in periphery opaque spots, improved after 5 months of cortisone treatment, MS diagnosis made by lumbar puncture, different sensitivity to heat in hands, feelings of having a “spiderweb” in her head, physical effort accompanied by an “electric shock” from head to toes (“coup de l’ermite”), headaches, migraine

10 amalgams, filling removed from 1995-6

1.98: paraesthesia completely disappeared, current neurologist doubts previous MS diagnosis, fewer headaches and migraine

own health assessment: much better

### **Patient No. 19** S.D., female 1941

symptoms: headaches, migraine, allergies

12 amalgams, 1<sup>st</sup> filling removed 3.91, last 3.92

9.92: patient feels much better healthwise

7.95: Mamma Ca operation with radiation

1.97: practically no more headaches, no more migraine

1.98: since 12-97 headaches a bit more often, possibly caused by heavy medication, allergies better

own health assessment: much better

### **Patient No. 20** Z.E., male 1929

symptoms: hip and hernia pain, unaccountable shoulder / arm pains (muscle inflammation), cannot lift arm, no strength in arm, stomach problems

12 amalgams, 1<sup>st</sup> filling removed 7.95, last 2.96

12.95: fewer pains, cortisone discontinued

7.96: no more shoulder problems

10.97: same, full strength regained in shoulder

own health assessment: much better

### **Patient No. 21** S.M., female 1950

symptoms: neck tension, arthritis in fingers, paraesthesia

16 amalgams, 1<sup>st</sup> filling removed 5.95, last 12.95

12.95: no more arthritis in fingers, slight neck tension

7.96: no more arthritis, paraesthesia

7.97: steady improvement

own health assessment: much better

### **Patient No. 23** R.G., female 1949

symptoms: exhaustion, eye problems (double vision at cinema, flickering) stomach / intestinal problems, migraine, neck tension, depression

11 amalgams, 1<sup>st</sup> filling removed 6.93, last 8.97

8.97: continued gastro-intestinal disturbances, health considerably better, no more neck tension, considerably less headaches, no more eye problems, mental stability

4.98: stomach / intestinal problems better, exhaustion disappeared, mental improvement

own health assessment: much better

## Health Observations Before and After Amalgam Removal

### **Patient No. 24** D.D., female 1934

symptoms: migraine originating in the neck, rheumatism, insomnia, depression, stomach / intestinal problems

13 amalgams, 1<sup>st</sup> filling removed 9.95, last 5.96

5.96: fewer headaches and migraine, less depression

11.96: headaches much better, less tired, insomnia improved, depression much better

6.97: health much better except for gastro-intestinal disturbances

4.98: further health improvement, less tired, better sleep, no more stomach burning, mentally more stable

own health assessment: much better

### **Patient No. 25** T.G., female 1950

symptoms: migraine, speech impaired, partial paralysis

19 amalgams, 1<sup>st</sup> filling removed 9.95, last 5.96

1.97: far fewer migraine

own health assessment: much better

### **Patient No. 26** R.U., female 1950

symptoms: dizziness, headaches, migraine, heart trouble (arrhythmia), paraesthesia in arms, stomach /intestinal problems, "inner nervousness", penicillin allergy

9 amalgams, 1<sup>st</sup> filling removed 9.95, last 10.96

9.96: fewer headaches, less paraesthesia, less dizziness

11.96: gastro-intestinal disturbances, less nervous

own health assessment: much better

### **Patient No. 27** T.M., female 1957

symptoms: neck tension, pain when lifting arm, hair combing impossible, back pain, neurological eye problems (ground or floor appear closer than in reality), dizziness, hand trembling, paraesthesia in hands, flatulence

10 amalgams, 1<sup>st</sup> filling removed 9.95, last 5.97

11.95: Healthwise better, ability to move arm, dizziness gone

3.96: dizziness gone, paraesthesia disappeared, no more pain, less stomach problems

1.98: practically all health-related problems gone

6.98: no more back problems, can go camping with children

own health assessment: much better

### **Patient No. 28** B.C., 1948

symptoms: paraesthesia mostly in hands, frequently severe sore throat, tiredness, joint pain, digestion disorder

16 amalgams, 1<sup>st</sup> filling removed 10.95, last 3.96 (titanium implant 47 removed)

11.96: continued throat pains, fewer joint aches, continued digestion problems (diarrhea, gas)

continued paraesthesia in hands as well as feet

4.98: continued joint pain, but no as good as a year before

own health assessment: somewhat better

### **Patient No. 29** Z.K., 1957

symptoms: stomach / intestinal problems, joint complications (rheumatism inflammation in iliosacral region) numerous sore throats, weight gain, very large lymph nodes, frequent earaches, multiple allergies, severe back problems for 6 years, previously very fit, very low blood pressure, psychic problems, continuous feeling of sickness

13 amalgams, 1<sup>st</sup> filling removed 2.96, still 4 fillings undone

3.96: health deterioration after amalgam removal

11.96 and 1.97: repeated serious reaction to amalgam removal, wishes to wait for the removal of the last 4 amalgams, fear of recurring reaction

4.98: decision to have the four remaining fillings removed



## Health Observations Before and After Amalgam Removal

### **Patient No. 30** G.R., male 1962

symptoms: headaches, back pains

11 amalgams, 1<sup>st</sup> filling removed 11.95, still 5 fillings undone

12.95: severe headache reaction to the removal of 3 fillings

8.97: far fewer headaches

9.97: repeated severe reaction to the removal of another filling, decides to wait in fear of a renewed reaction to an amalgam removal

### **Patient No. 31** N.P., male 1960

symptoms: sight impairment, larynx pains, skin rash, acute diarrhea, insomnia, neck tension, migraine, paraesthesia, memory disorder

9 amalgams, 1<sup>st</sup> filling removed 11.95, last 3.9

10.96: no more depression after 2-3 months of single treatment, after filling removal no more headaches, larynx pains gone, skin rash gone, vision disturbances, insomnia improvement, continued migraine but less frequent, paraesthesia gone, memory still irregular

own health assessment: somewhat better

### **Patient No. 33** K.P., female 1932

symptoms: gastro-intestinal disturbances (colon) . Stomach to back pains leading to leg pain, joint problems in fingers, nausea in the morning, paraesthesia in legs and head, pains, ocular problems, joint problems, continuous uneasiness

8 amalgams, 1<sup>st</sup> filling removed 11.95, last 6.96

6.96: no more head throbs or uneasiness

11.96: much less paraesthesia, fewer gastro-intestinal disturbances

own health assessment: much better

### **Patient No. 34** E.G., male 1974

symptoms: allergies, severe headaches, migraine with signs of paralysis (cannot walk, speak or hear), dizziness, ocular and ear trouble, uses solvents (formaldehyde) at work

3 amalgams, 1<sup>st</sup> filling removed 2.96, last 2.96

2.96: less frequent migraine, continuously severe headaches

9.96: less dizziness, less severe migraine without any signs of paralysis

4.97: more frequent headaches and increased dizziness, but health improved overall

own health assessment: better

### **Patient No. 35** B.S., male 1957

symptoms: headaches, nose always stuffy (liquid secretions), sleep interruptions, bad concentration, memory loss

10 amalgams, 1<sup>st</sup> filling removed 1.96, last 4.96

1.96: severe shoulder /neck pain after first amalgam is removed

2.96: same

4.96: far better health, no headaches, more energy, even less shoulder pain, no more stuffed up nose, better concentration

own health assessment: much better

### **Patient No. 36** G.K., male 1951

symptoms: migraine, strong headaches, unaccountable losses of consciousness since 1990 (resulting from whiplash injury after a head-on collision)

9 amalgams, 1<sup>st</sup> filling removed 3.96, last 8.96

8.96: significantly fewer headaches

own health assessment: much better

### **Patient No. 37** H.H., male 1944

symptoms: severe allergy in arms, legs and throat with danger of suffocation (always carries cortisone spray) several times a year, shoulder pain when carrying postal parcels (doctor thinks it is "wear and tear")

12 amalgams, 1<sup>st</sup> filling removed 1.94, last 12.95

1.97: allergies disappear

4.98: no more shoulder pains whatsoever

own health assessment: much better

## Health Observations Before and After Amalgam Removal

### **Patient No. 41** M.W., male 1940

symptoms: severe and long-lasting migraine, dizziness, paraesthesia mainly in arms, extreme vomiting spasms, back pains, neck tension

7 amalgams, 1<sup>st</sup> filling removed 6.96, last 3.97

12.97: no migraine, paraesthesia or dizziness whatsoever, feels “reborn”

6.98: no more migraine whatsoever, feels much more stable mentally, says that neck tension and back pain have disappeared, feels “like 20” again

own health assessment: much better

### **Patient No. 42** H.M., female 1962

symptoms: many migraine and dizzy spells

10 amalgams, 1<sup>st</sup> filling removed 4.96, last 1.98

1.98: less migraine, dizziness gone

own health assessment: much better

### **Patient No. 43** R.C., female 1964

symptoms: pharyngitis, laryngitis, frequent angina, tension headaches

3 amalgams, 1<sup>st</sup> filling removed 8.96, last 10.96

1.97: less frequent but still severe headaches, pharyngitis and laryngitis improved

own health assessment: somewhat better

### **Patient No. 44** G.H., male 1960

symptoms: MS

10 amalgams, 1<sup>st</sup> filling removed 9.96 last 1.97

1.97: no improvement

own health assessment: worsening

### **Patient No. 45** C.R., male 1942

symptoms: gastro-intestinal disturbances, migraine

18 amalgams - some under crowns - 1<sup>st</sup> filling removed 8.96, last 1.97

1.97: no improvement

own health assessment: worsening

### **Patient No. 46** S.W., male 1924

symptoms: inexplicable fatigue, diabetes

10 amalgams, 1<sup>st</sup> filling removed 6.96, last 1.97

1.97: patient feels better and has more energy

3.98: patients feels more tired

own health assessment: worsening

### **Patient No. 48** S.J., male 1948

symptoms: very frequent head pains, stomach trouble (acidity), skin problems, paraesthesia

15 amalgams, 1<sup>st</sup> filling removed 3.93, last 2.97

9.97: no more head pains or stomach problems

own health assessment: much better

### **Patient No. 49** H.R., female 1946

symptoms: headaches, migraine, dizziness, eye trouble, hand paraesthesia, neck tension, feels uneasy

12 amalgams, 1<sup>st</sup> filling removed 12.93, last 2.97

4.97: health greatly improved, hardly any migraine

8.98: migraine practically gone, health improvement “like day and night”

own health assessment: much better

### **Patient No. 50** S.E., female 1953

symptoms: migraine, dizziness, tension, unaccountable strong pain in shoulder area, tennis ball-size lump (“no doctor can tell me what it is”)

13 amalgams, 1<sup>st</sup> filling removed 9.96, last 6.97

11.96: stomach / intestine much better, hardly any migraine

11.97: chest pains completely gone

7.98: further health recovery

own health assessment: much better

## Health Observations Before and After Amalgam Removal

### **Patient No. 51** M.S., female 1943

symptoms: chronic colds, allergies, asthma, headaches, migraine, fatigue  
3 amalgams, 1<sup>st</sup> filling removed 5.96, last 7.96  
12.96: fewer colds, less asthma but continued headaches and migraine  
2.97: same  
own health assessment: somewhat better

### **Patient No. 52** S.E., female 1941

symptoms: polyarthritis, migraine (from lower rear skull and temples to behind the eyes)  
5 amalgams, 1<sup>st</sup> filling removed 3.96, last 7.96  
7.97: a bit less migraine, monthly instead of weekly before  
1.98: same  
own health assessment: somewhat better

### **Patient No. 53** W.L., female 1936

symptoms: headaches, allergies, sinusitis  
10 amalgams, 1<sup>st</sup> filling removed 5.96, last 9.96  
9.96: fewer headaches, sinusitis inflammation but still has allergies  
own health assessment: better

### **Patient No. 54** T.K., female 1947

symptoms: dizziness (medical diagnosed as Meniere disease), double vision, migraine  
tooth 27 removed in 11.92, less dizziness since then  
7.96: less dizziness  
11.97: continued recovery, practically no more dizziness  
own health assessment: much better

### **Patient No. 55** S.H., female 1963

symptoms: migraine, sensitive to light, pressure behind eyes, nausea, gastro-intestinal disturbances, dizziness  
14 amalgams, 1<sup>st</sup> filling removed 2.96, last 11.96  
1.97: much less often migraine is more like a headache. gastro-intestinal: can once again tolerate certain food which was previously unbearable  
own health assessment: much better

### **Patient No. 57** M.S., female 1931

symptoms: stuffy nose, allergies, inexplicable fatigue, swollen lymph glands from behind the head to throat, stomach ache, takes cortisone, eczema on hands and feet  
12 amalgams, 1<sup>st</sup> filling removed 5.96, last 6.97  
6.97: minimal health improvement  
3.98: eczema disappeared, continued stuffy nose, continued asthma, much less tired, mentally far better off  
own health assessment: much better

### **Patient No. 58** S.H., male 1937

symptoms: migraine, tingling in legs, Tinnitus for 18 years  
15 amalgams, 1<sup>st</sup> filling removed 5.95, last 10.96  
1.96: migraine and paraesthesia considerably better, continued Tinnitus  
1.98: same  
own health assessment: better

### **Patient No. 59** V.J., male 1944

symptoms: asthma, backache, neck tension, migraine, metal taste  
5 amalgams, 1<sup>st</sup> filling removed 6.96, last 12.96  
4.97: less migraine, asthma still not good  
9.97: not more migraine, asthma still not good  
1.98: recurrence of backache, migraine and asthma  
own health assessment: somewhat better

## Health Observations Before and After Amalgam Removal

### **Patient No. 60** H.S., female 1943

symptoms: MS  
6 amalgams, 1<sup>st</sup> filling removed 7.94, last 6.96  
3.97: no improvement  
own health assessment: worsening

### **Patient No. 61** D.C., female 1979

symptoms: has had strong migraine with nausea for 1-2 years, 4 occlusal fillings by us 8 years before  
4 amalgams, 1<sup>st</sup> filling removed 5.96, last 7.96  
7.96: migraine weaker but still some dizziness  
5.97: migraine and neck tension disappeared  
own health assessment: much better

### **Patient No. 63** J.F., female 1956

symptoms: neurodermatitis (severe and painful itch on face, throat, chest and underarms (somewhat alleviated by cortisone cream)  
11 amalgams, 1<sup>st</sup> filling removed 12.95, last 3.96  
3.96: no more neurodermatitis  
11.96: no more allergies  
2.98: no more neurodermatitis whatsoever (cortisone discontinued over a year before)  
own health assessment: much better

### **Patient No. 64** E.C.

symptoms: low blood pressure, headaches, frequent vocal chord troubles  
8 amalgams, 1<sup>st</sup> filling removed 10.96, last 3.97  
7.97: fewer headaches, continued vocal chord trouble  
own health assessment: better

### **Patient No. 65** W.R., male 1943

symptoms: after whiplash injury concentration, memory and hearing problems, sensitive to electromagnetic fields, forced to reduce to part-time work, Tinnitus, headaches, joint trouble  
9 amalgams, 1<sup>st</sup> filling removed 1.97, last 4.97  
4.97: generally feels better  
own health assessment: much better

### **Patient No. 67** M.H., female 1940

symptoms: joint pains, neck tension, shoulder /arm pains  
6 amalgams, 1<sup>st</sup> filling removed 7.87, last 7.87  
3.97: overall health improvement  
3.98: joint pains and neck tension disappear, no more shoulder /arm pains  
own health assessment: much better

### **Patient No. 68** H.M., male 1960

symptoms: headaches, migraine, gastro-intestinal disturbances (Crohn related?)  
6 amalgams, 1<sup>st</sup> filling removed 6.96, last 1.97  
2.97: no more migraine, far fewer headaches  
2.98: previous migraine in 12.97 (frequent then , no more now), continued gastro-intestinal disturbances  
own health assessment: much better

### **Patient No. 69** K.E., female 1954

symptoms: hair loss, left shoulder pain radiating to the front of the arm and chest, psychic difficulties (fear), stomach burns,  
15 amalgams, 1<sup>st</sup> filling removed 6.96, last 11.96  
11.96: no more shoulder pain  
2.97: much less hair loss  
9.97: no more stomach burns, no hair loss, psychically better  
own health assessment: much better

## Health Observations Before and After Amalgam Removal

### **Patient No. 71** K.J., female 1935

symptoms: cardiac dysrhythmia, paraesthesia in arms and legs, dizziness, headaches  
4 amalgams, 1<sup>st</sup> filling removed 4.96, last 4.96  
2.97: headaches done, noticeable “hole in the head” feeling gone, paraesthesia  
3.98: continued improvement  
own health assessment: much better

### **Patient No. 72** J.N., female 1970

symptoms: light sensitivity, ocular problems (cannot tolerate sunlight), back pains, onset of paralysis (numbness, radiating to elbows, then to shoulders, and finally knees), speech impairment severe memory loss (total loss after two minutes in remembering what she had eaten, what train she was on and in what direction  
15 amalgams, 1<sup>st</sup> filling removed 9.95, last 5.96  
3.96: less dizziness, no more speech impairment, less paralysis  
4.96: severe reaction after amalgam removal (trouble moving arm)  
5.96: repeated severe reaction after amalgam removal  
7.96: no more paralysis in arms, short-term memory better, when tired still problems finding words, continued severe back pains, much less sensitive to light, fewer ocular trouble, less hay fever  
3.97: overall health much better  
3.98: continued health improvement (“lives again”)  
own health assessment: much better

### **Patient No. 73** V.A., female 1943

symptoms: “buzzing” in whole body, slight trembling whole body, dizziness, back tension, migraine, heart murmurs  
9 amalgams, 1<sup>st</sup> filling removed 5.89, last 4.95  
9.91: less dizziness and fewer heart murmurs, shorter migraine, “buzzing” in body completely disappeared  
1.98: all symptoms practically gone, no more heart murmurs  
own health assessment: much better

### **Patient No. 74** K.H., female 1930

symptoms: dizziness (medical diagnosis: Meniere disease), muscle pain, migraine, nausea  
13 amalgams, 1<sup>st</sup> filling removed 11.95, last 6.96  
4.96: far less dizziness and nausea  
4.97: steady health improvement  
own health assessment: much better

### **Patient No. 75** J.K., male 1937

symptoms: headaches (this his doctor believes comes from his neck vertebra), sensitivity to changes in weather  
7 amalgams, 1<sup>st</sup> filling removed 7.95, last 6.97  
5.97: sensitivity to changes in weather, no more headaches, no more dizziness  
own health assessment: much better

### **Patient No. 76** K.B., female 1960

symptoms: allergies, fatigue, stomach /intestinal problems, sight impairment  
7 amalgams, 1<sup>st</sup> filling removed 8.95, last 6.97  
6.97: skin less dry, much less tired, less sight impairment, fewer gastro-intestinal disturbances, general feeling of well-being  
8.98: no more sight impairment, skin and stomach much better  
own health assessment: much better

### **Patient No. 77** F.A., female 1957

symptoms: neck tension, frequent migraine, stomach problems, hair loss, sinusitis  
18 amalgams, 1<sup>st</sup> filling removed 6.95, last 8.97  
8.97: much less migraine, general feeling of well-being  
own health assessment: much better

## Health Observations Before and After Amalgam Removal

### **Patient No. 78** F.M, female 1955

symptoms: neck tension, back pain, migraine, headaches, gastro-intestinal disturbances, mental imbalance  
10 amalgams, 1<sup>st</sup> filling removed 3.97, last 10.97, possibly another amalgam under the 4 crowns  
10.97: overall health improvement  
1.98: continued migraine and neck tension, stomach /intestines better, depression gone, general feeling of well-being, less “fogginess” in the head, strong taste for life like before  
own health assessment: much better

### **Patient No. 79** I.C, female 1958

symptoms: hayfever, neck tension, migraine  
6 amalgams, 1<sup>st</sup> filling removed 12.95, last 6.96  
11.96: continued severe migraine believed to be closely connected with smoking  
8.97: somewhat fewer migraine, far fewer allergies, no more hay fever, neck improved  
own health assessment: better

### **Patient No. 80** M.A., female 1938

symptoms: neck tension, migraine, headaches  
13 amalgams, 1<sup>st</sup> filling removed 3.95, last 6.96  
9.97: migraine disappeared, much less neck tension, only occasional headaches  
7.98: further health improvement, no more neck problems (can back up while driving again), very occasional headaches, no more lower back pain at all  
own health assessment: much better

### **Patient No. 81** H.M., female 1949

symptoms: chronic headaches, frequent numbness in right hand  
15 amalgams, 1<sup>st</sup> filling removed 2.96, last 10.96  
10.96: less paraesthesia in hand, far fewer headaches  
1.98: headaches during menstruation, less numbness in hand, feels much better than ever before  
own health assessment: much better

### **Patient No. 82** G.E., male 1925

symptoms: arthritis in fingers, paraesthesia  
17 amalgams, 1<sup>st</sup> filling removed 3.96, last 1.98  
1.98: much less arthritis in fingers, much less swollen and deformed  
own health assessment: much better

### **Patient No. 85** M.C., female 1958

symptoms: exhaustion, digestive trouble, neck tension  
17 amalgams, 1<sup>st</sup> filling removed 2.96, last 7.97  
5.97: strong reaction to amalgam removal (exhaustion symptoms)  
7.97: same  
1.98: much less neck tension, digestion improved, less exhausted, less “fogginess” in head  
own health assessment: much better

### **Patient No. 86** M.M., female 1938

symptoms: back pains, shoulder problems (periarthritis), neck tension  
13 amalgams, 1<sup>st</sup> filling removed 8.92, last 1.93  
3.97: claims to feel better and to be less mentally distressed  
1.98: continued back and shoulder problems, less neck tension  
own health assessment: much better

### **Patient No. 87** S.A, female 1967

symptoms: migraine  
4 amalgams, 1<sup>st</sup> filling removed 7.97, last 9.97  
1.98: believes migraine to be milder and only when menstruating  
own health assessment: better

## Health Observations Before and After Amalgam Removal

**Patient No. 88** R.S, female 1963

symptoms: very strong hay fever, burning sore throats, severe neck pain, shoulder pains (unable to carry handbag on shoulder), migraine

7 amalgams, 1<sup>st</sup> filling removed 1.95, last 7.96

7.96: no more migraine, less neck tension

4.98: no neck tension whatsoever, no more migraine, no more hay fever for two years, no more sore throats, no more shoulder problems

own health assessment: much better

## Appendix

The preceding paper was the basis for the editorial and the report which appeared in PULStipp magazine (No 11, 6 November 2001, Zurich):

### **Suspicious dentist now believes patients**

#### **Editorial**

*By Urs P. Gasche*

Headaches, migraine, neck tension and gastro-intestinal ailments had disappeared in almost all of 52 female and 23 patients. Some also felt as if all joint or back pains, allergies or visual disturbances after having the amalgam fillings removed from their teeth had been blown away.. For Paul Engel, a Swiss dentist from Biel, this is “an almost unbelievable result”. Never would he have expected such an outcome after having treated his patients with amalgam for twenty years. He had considered the use of amalgam fillings before as “highly reliable”.

Therefore, he remained extremely skeptical when some of his patients wished to have their intact amalgam fillings replaced with composites. All these patients suffered from health problems. But they had heard from friends or in medical broadcastings (e.g. “Kassensturz” in Swiss TV) that mercury vapors from amalgam fillings could have toxic effects by certain patients. The suspicious dentist agreed remove their amalgams but decided to keep a exact record of these patients' health.

Today there is no doubt for him that amalgam fillings had been responsible for headaches, migraine, neck tension, gastro-intestinal problems and other ailments as well. Even soon after amalgam removal 60 out of the 75 women and men were feeling “much better” or at least “better”. Today - several years later - the lost aches and pains have not reappeared. New patients with resembling experiences – up to 160 total - have come to similar conclusions concerning their health improvement (see the following report by Claudia Peter) . In the meantime, Paul Engel is convinced that amalgam not only accounts for 5 percent of people's sicknesses. With much concern he asks himself “How many with similar health problems are there in my other patients?”



## **Amalgam was guilty**

### **Our teeth may be the cause of chronic disease**

#### **Report**

*by Claudia Peter*

A dentist from Biel would not believe it for a long time. He followed the health record of 160 of his patients with skepticism. However, it has become increasingly clear for him: in retrospect, dental amalgam was responsible for many persistent chronic diseases.

At the age of nine Ursula Mueller lost her long, blond hair. It fell out patch by patch. Splitting headaches soon followed. Sometimes the child fainted at school. At age twelve, she was diagnosed with rheumatism and arthritis. Frequently she felt profoundly sick. She could hardly eat. Almost every cold ended in sinusitis, a chronic inflammation of her nasal sinus. In addition, she was plagued by psychic problems. As an adult Ursula Mueller still suffered from severe depressions. "No doctor could help me", she remembers. "Each symptom was treated separately. And no one ever had the idea that all of my complaints might have a common cause."

Ursula Mueller became female patient number four in the study of the dentist Paul Engel. She is one of more than 160 patients whose amalgam fillings were removed under dentist Engel's care during the last eight years. Engel followed their state of health closely after the removals. The result: one year later four fifths of the patients qualified their state of health as "much better" or "better". These results show clearly: amalgam removal can permanently heal or greatly improve a wide range of physical and psychic disorders.

#### **Patients' concrete stories forced Engel to change his view.**

Ursula Mueller feels healthy today. Eight years ago her doctor diagnosed her with "amalgam intoxication" and wrote a certificate stating she was partially unable to work. And today? Ursula Mueller works full time as a primary school teacher again. "My whole body is rid of mercury from amalgams" she says proudly. The complaints which had been troubling her more than twenty years are a thing of the past.

Dentist Engel has published the detailed case histories of Ursula Mueller and his other amalgam patients in the Swiss monthly dentist publication SSO. For a long time he shared the belief of most of his professional colleagues that doubts towards amalgam were simply "hysteria". But these patients' case histories modified his opinion radically. Today he is convinced: "Amalgam does not belong in the mouth. It can poison the body slowly, but chronically."

This is concurrent with recent scientific findings. Veterinary research has shown that mercury can rapidly move into sensitive organs. Canadian researchers put amalgam fillings into the teeth of sheep and apes. Only one month later they discovered mercury deposits in the stomach, intestine, kidneys and gums of these animals. The kidney function of mercury-burdened sheep was reduced by half.

In humans mercury gradually builds up in the brain, the central nervous system and kidneys. This has been seen in autopsies. The more amalgam fillings doctors found on a deceased person, the greater the quantity of mercury in his or her organs.

Deceased Alzheimer patients show a substantially higher concentration of mercury in their brains than other humans. Two Swiss scientists from Basel, Hannes Staehelin and Gianfranco Olivieri have found through laboratory researches that mercury does in fact play an important role in the development of Alzheimer's disease. The same is feared with other diseases such as Parkinson and multiple sclerosis.

Mercury damages the health of unborn children and nursed infants. The more amalgam fillings there are in a mother's mouth, the greater the mercury concentration that can be found in her placenta and milk.

If mercury, which evaporates from amalgam fillings, is really that dangerous, why don't more humans fall ill? This question has been pursued by a German toxicologist, Gustav Drasch, in the Philippines. On behalf of the UN, Drasch examined workers in mountainous gold mining areas. These humans come into daily contact with mercury from the mines. "Nobody can dismiss them as amalgam cranks", declares Drasch. The disease symptoms these workers suffered were very different from each other. Some of them could hardly stand up straight, others went about their work as usual, even though Drasch found high mercury concentrations in all their bodies.

"There is no limit, below which mercury can't cause ailments", concludes he. "Some humans are healthy despite increased concentration of mercury in their body – whereas others fall ill at the slightest trace of the metal".

This was the case of Swiss school boy Tin Curtins. A single amalgam filling threw him completely off course. The previously healthy boy experienced severe migraine. "I had to come home from school and go straight to bed, so I could lie down until the pain faded", he recalls. This occurred up to three times a week. A holistic doctor, who treated the boy, said Tin showed clear symptoms of mercury intolerance. She recommended he should have his lone amalgam filling removed.

But after Engel had removed the filling, Tin's migraine intensified instead of disappearing. The dentist consoled the desperate boy: "These things happen. The process of removing a filling can temporarily increase a patient's mercury burden even if the dentist is careful". He told Tin not to give up hope. Today, more than a year after treatment, the teenager is completely free of any major health problems.

In spite of these evident health improvements after amalgam removal Swiss dental experts have expressed reservations. Professor Adreian Lussi, amalgam expert at the University of Berne, misses a control group in Engel's study. "An appropriate control would have been a group of patients with amalgam fillings and the same health problems, who refused removal", he explains. "A comparison of the two groups would have shown whether it was actually the amalgam removal which improved patients' health."

Professor Jakob Wirz of the University of Basel is convinced that the complaints Engel's patients expressed were mainly caused by their psychic condition and their environment. "Amalgam only serves as a scapegoat here", he criticizes. "It is still the best and most extensively examined material used in dental medicine."

### **A comparative study is long overdue.**

"I am a dentist, not a scientist", Engel responds. "I published my observations, nothing more. The rest I must leave to the professors". Engel is surprised why none of the Swiss dental faculties ever

published such a comparative study with amalgam patients, even though Adrian Lussi clearly states: "Amalgam does release mercury. This much we are sure of."

Scientists at Swiss universities have nevertheless always contested that mercury in the body causes widespread organic damage. At most, they contend, only a few people should be fall victims of this condition.

As for patient Georges Krattinger, he never believed he could possibly belong to the amalgam-sensitive people. "15 years ago I watched a television broadcast on amalgam", he remembers. "I simply laughed at it". Therefore, it never occurred to him that his chronic migraine might be caused by his amalgam fillings. In due course, Engel removed several of his amalgam fillings and replaced them with composites - without telling him that amalgam could have something to do with his complaints. Later Engel inquired about his patient's health: Krattinger reported that his migraine attacks had decreased. The time frame corresponded exactly with the period after the fillings had been removed.

Now Krattinger wanted to know whether his 66-year-old wife Jeanette suffered from chronic mercury poisoning as well. At age 30 she had developed heartbeat rhythm- and blood circulation disturbances. Later dizziness occurred frequently. So Jeanette Krattinger had her fillings removed as well. In fact: her state of health improved likewise - slowly, but steadily. Today her dizziness attacks and heartbeat irregularities have decreased "considerably". Jeanette Krattinger states: "An amalgam filling will never enter my mouth again". Her husband now opted for the radical cure and had Engel remove all his remaining amalgam fillings. Result: Georges Krattinger no longer suffers from migraine attacks at all.

"Amalgam is by far not the only cause of a patient's health problems, Engel thinks. "But it plays an important role, probably more frequently than we would like to think."